EVALUATING A FOAM DRESSING IMPREGNATED WITH 0.5% POLYHEXAMETHYLENE BIGUANIDE (PHMB) IN THE MANAGEMENT OF INFECTED VASCULAR ULCERS

Neves G., Serra Perucho N., Hernández V., Prades M., Mestres Sales J. Mª.

Angiogrup. Barcelona.

INTRODUCTION:

Vascular ulcers frequently become infected due to the slow healing process, which allows a higher exposure to bacteria in the environment. This may further delay healing, cause pain and diminish the quality of life of the patient. In some cases where there is the lack of sensation caused by a diabetic neuropathy, patient consultation may be delayed due to late presentation of a wound in the foot in an advanced stage of infection, possibly even with osteomyelitis.

OBJECTIVE:

- Evaluate the effectiveness of a new dressing in the management of infected or heavily colonized wounds.
- Control and evaluate the pain during treatment.

MATERIAL AND METHODS

A study was carried out on 10 patients with lower limb ulceration of vascular or trauma etiology, using a foam dressing impregnated with 0.5% PHMB. Before initiating the treatment the ankle-brachial pressure index was measured and angiography was performed to confirm the leg ulcer diagnosis, and a wound swab was taken to determine the infection status.

The wounds were followed up for four weeks with the trial dressing in use, and the frequency of dressing change every 3 or 4 days. Once the signs and symptoms of infection were reduced, the treatment was changed to moist wound healing management using advanced wound care dressings

RESULTS AND CONCLUSION

In 9 of the 10 patients the wounds progressed with satisfactory results. In the remaining patient there was no change in the condition of the wound due to scleroderma.

The results of our experience with the foam dressing impregnated with 0.5%PHMB included in this study are encouraging:

- It appeared to facilitate debridement of devitalized tissue in the wound
- Patients reported a decrease in pain during the use and change of the dressing
- Where the dressing was used under compression therapy there was a vertical absorption of exudate, providing the protection of the peri- wound skin.
- Most of the patients who were treated showed a reduction in the signs and symptoms of infection. This was evaluated clinically, however no cultures were undertaken to confirm these results.

DISCUSSION

Possibly PHMB's homogeneous distribution is a positive factor in the efficiency of the dressing since it guarantees equal levels in the whole surface of the wound and the control in surface´s bacterias. Further studies be done to compare the placement of dressings and PHMB separately.

DIABETIC FOOT

POSTHEMATOMA ULCER

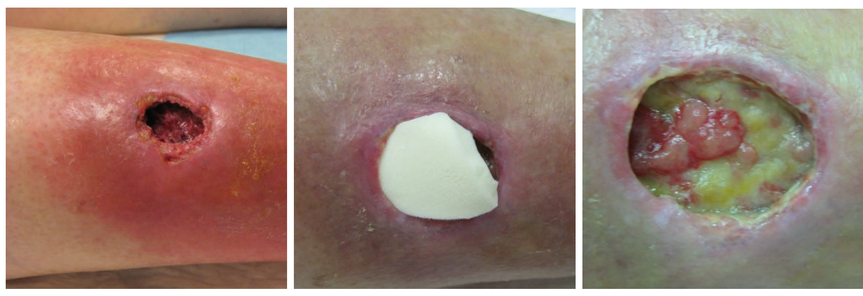

POSTHROMBOTIC ULCER

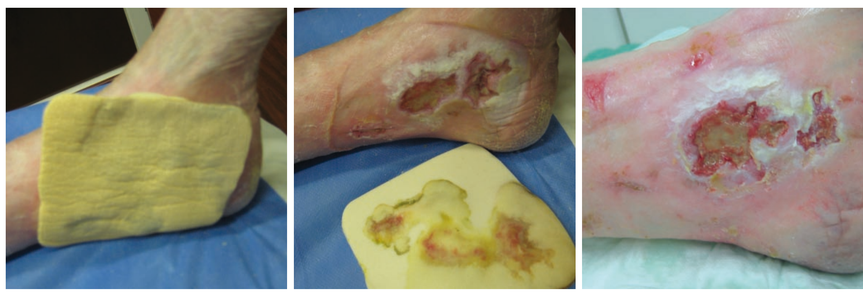

TRAUMATIC ULCER

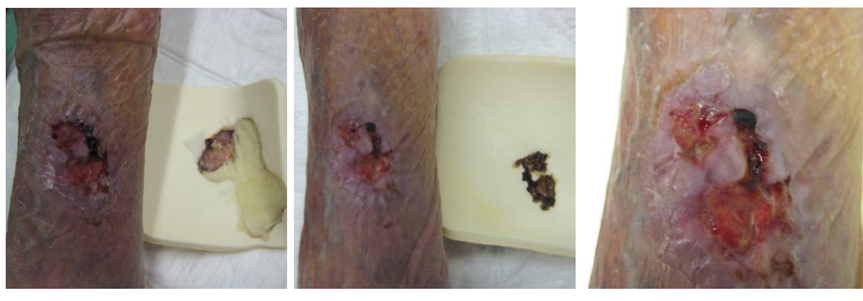

VENOUS ULCER