

# A Review of a Foam Dressing Containing 0.5% Polyhexamethylene Biguanide Under Compression Therapy in the Management of Lower Limb Ulceration

Sylvia Stanway, Clinical Nurse Specialist: Tissue Viability, NHS Salford, Salford Community Care, Salford; Pam Spruce, Clinical Director, TVRE Consulting, UK

## Introduction

The use of compression bandages is now recognised as the first line in treatment for patients with lower limb ulceration, where venous hypertension is a contributory factor. While many patients progress to healing with this therapy without developing any complications, there are still some who need additional care in order to achieve a positive outcome. A number of patients treated for leg ulcers within Salford Primary Health Care Trust present with wounds where the risk of infection is identified, or exudate management requires additional treatment. These are cases where a topical antimicrobial dressing may be considered.

## Method

A three week evaluation of the Kendall™ AMD antimicrobial foam dressing (Tyco Healthcare Group LP d/b/a Covidien, Mansfield, MA, 02048, USA), a foam dressing impregnated with 0.5% polyhexamethylene biguanide (PHMB), was undertaken in 5 patients with lower limb ulceration. While it was initially planned to review its use under compression therapy only, it was decided to extend the evaluation due to the wide variety of patients who attend the service for treatment.

The aim of this evaluation was:

- To observe whether the dressing was effective at managing exudate, and therefore where appropriate contribute to a longer wear time for compression therapy.
- To evaluate whether the dressing contributed to the reduction in wound odour.
- To obtain patient feedback on the comfort of the dressing under compression therapy.
- To observe how the dressing as a bacterial barrier helped to prevent the clinical signs and symptoms of infection.

At each dressing change, information was collected on each patient and at the end of the evaluation the outcomes were reviewed.

## Results

An overview of the 5 patients is displayed in Table 1. This shows the range of different ulcer types and levels of compression that were used. The outcomes that resulted from this evaluation were as follows:

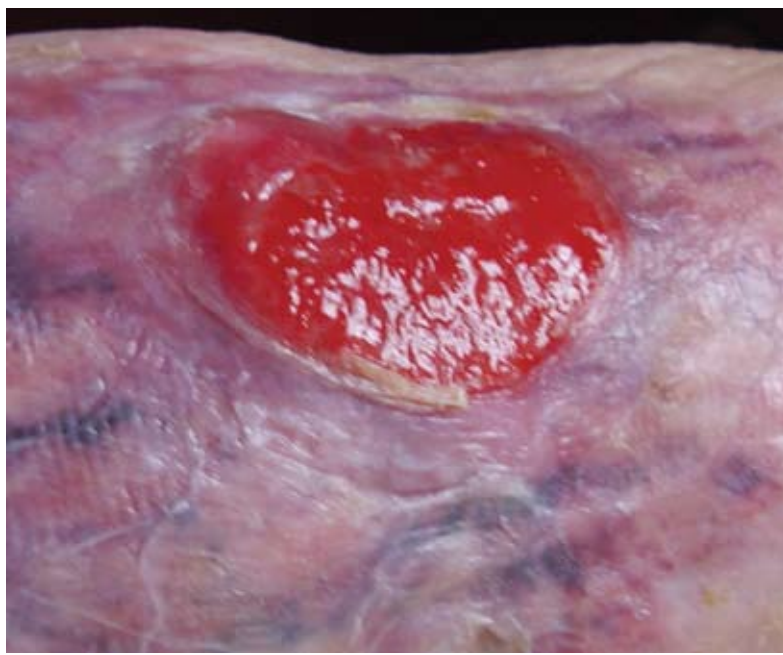- The wound size reduced in 4 out of the 5 patients.
- The level of exudate reduced in three patients.
- The frequency of dressing change was weekly in all patients.
- No patients were observed to have any increased signs and symptoms of infection.
- Where compression therapy was used, Kendall AMD antimicrobial foam dressing performed well in managing exudate. There were no signs of tissue maceration on the peri-wound margins.
- In all 5 cases, the patient described the dressing as comfortable.
- In all 5 cases, the clinicians recorded the dressing to be easy to apply and easy to remove without causing trauma to the wound bed.

## Patient Case Studies

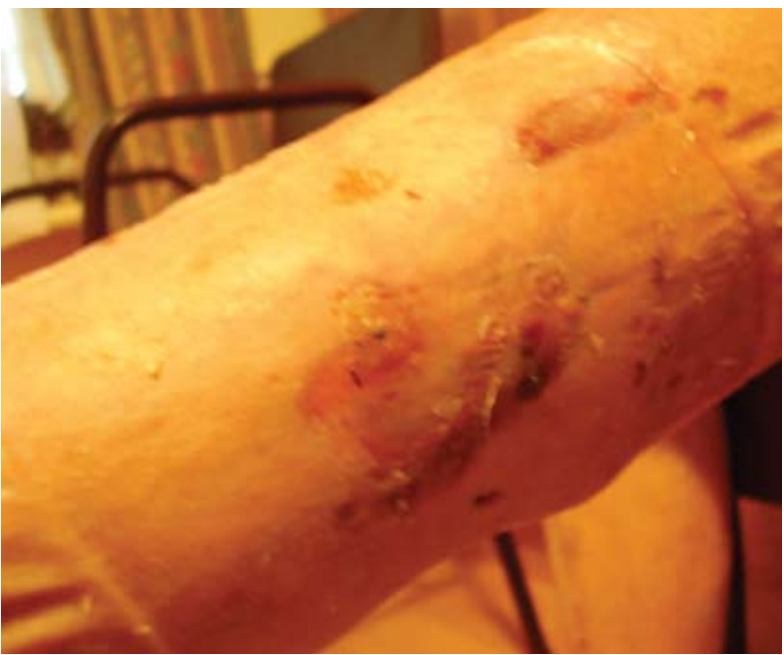### Patient 3

Patient 3 was an 88 year old patient who was treated with multi-layer compression for venous leg ulceration. At the start of the evaluation, the wound was demonstrating signs of a developing infection: increased levels of exudate, friable granulation tissue in the wound bed, and wound healing, which initially was progressing well, had now stalled (Photograph 1).

Kendall AMD antimicrobial foam dressing was applied under the compression bandages and changed weekly. At the end of the evaluation period, the wound had reduced in size and the level of exudate decreased (see Table 1). The tissue in the wound bed was healthy and the wound was progressing to healing as demonstrated in Photograph 2.



Photograph 1

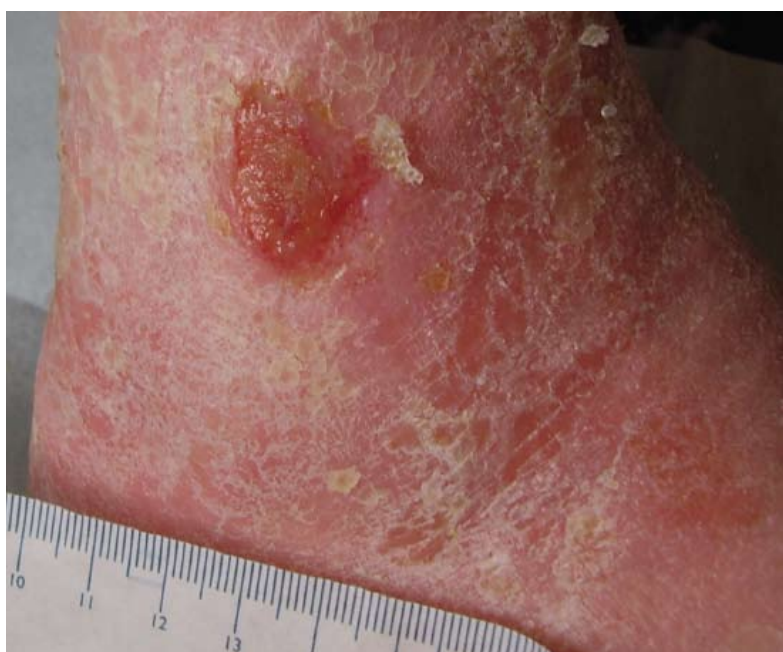

Photograph 2

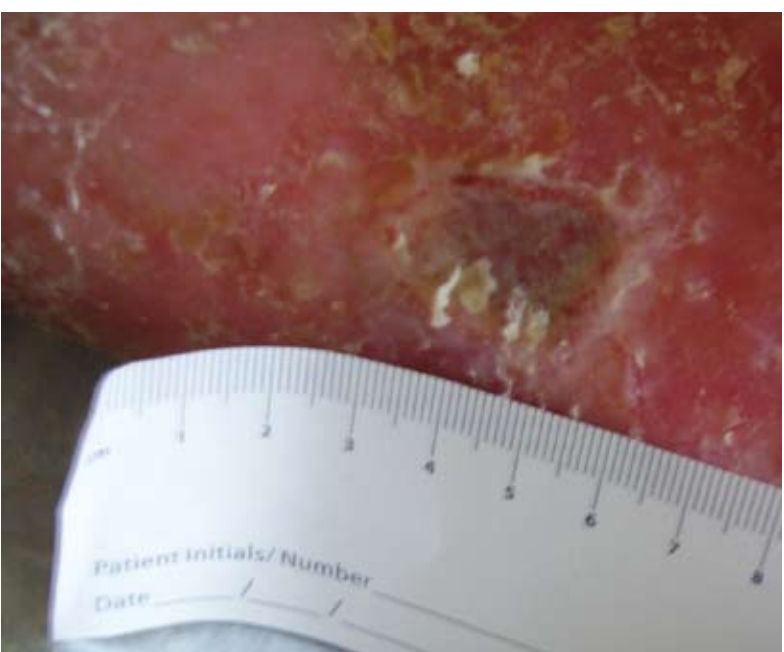### Patient 5

This lady was referred to the leg ulcer service for wound management and investigation of the ulcer (Photograph 3). It was suspected to be malignant, although the results of the biopsy diagnosed it to be a pyogenic granuloma.

Initially the Kendall AMD antimicrobial foam dressing was used as a bacterial barrier while the wound was investigated. It continued to be applied to the ulcer on a weekly basis, until at the end of the evaluation period the wound was observed to have healed. Photograph 4 shows the wound after two weeks treatment with the evaluation dressing.



Photograph 3: Prior to Kendall™ AMD antimicrobial foam dressing



Photograph 4: After two weeks with the Kendall™ AMD antimicrobial foam dressing

## Discussion


Although this was a small evaluation, it demonstrates the range of different lower limb ulcers that may present at a clinic and how the Kendall AMD antimicrobial foam dressing performed well in these patients. The dressing managed wound exudate, was comfortable for the 5 patients who participated in this evaluation, allowing them to receive therapeutic levels of compression where appropriate.

## Conclusion

Managing exudate and preventing infection are an ongoing challenge for clinicians who care for patients with leg ulcers. The aim of treatment is to achieve wound healing quickly and without complications. The Kendall AMD antimicrobial foam dressing is an appropriate choice as a dressing for lower limb ulceration.

Table 1

Patient Number	Patient Details	Type of Compression	Wound Size at Start of Evaluation	Wound Size at End of Evaluation	Exudate level at Start of Evaluation	Exudate level at End of Evaluation	Frequency of Dressing Change
1	Male 77 years – mixed aetiology leg ulcer	Class 2 compression hosiery	0.5 x 0.5cm	0.5 x 0.8cm	Moderate	Low	Weekly
2	Male 77 years – ulcer to base of great toe arterial	None	0.5 x 0.3cm	0.3 x 0.2 cm	Low	Low	Weekly
3	Female 88 years – venous leg ulcer	Multi-layer compression	3.1 x 2.9cm	0.5 x 0.7cm	Moderate	Low	Weekly
4	Female 85 years – mixed leg ulcer	Reduced compression	2.5 x 1cm	2 x 0.5 cm	Moderate	Low	Weekly
5	Female 93 years – suspected malignancy but diagnosed as pyogenic granuloma at biopsy	None	1cm x 0.7cm	Healed	Low	Low	Weekly



EWMA2010  
26-28 MAY - GENEVA  
WWW.EWMA2010.ORG

Presented at EWMA 2010.

This evaluation was sponsored by Tyco Healthcare Group LP d/b/a Covidien, Mansfield, MA, 02048, USA.

™Trademark of a Covidien company